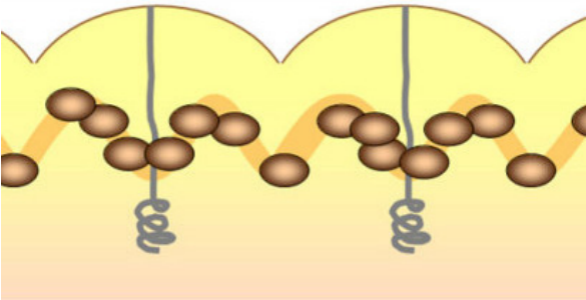


Benign melanocytic naevus: melanocytes are frequently clustered in the areas below the furrows of the plantar dermatoglyphics



Malignant melanoma: melanocytes and pigmentation extends and is accentuated onto the dermatoglyphic ridges of the plantar skin