Endometriosis

Marit C. I. Lier, Lisette E. E. van der Houwen en Velja Mijatovic

Life course

Although endometriosis typically impacts women of reproductive age, it also affects young adults, adolescents, and women in peri- and post menopause. Moreover, many adult endometriosis patients experience their first symptoms during adolescence. It's estimated that globally, over 175 million women suffer from endometriosis, with many experiencing significant individual and socioeconomic burden as a result. Endometriosis is present in half the patients who present with infertility or chronic pelvic pain. And although it is traditionally believed that pregnancy has a beneficial influence on endometriosis, its negative impact on pregnancy is currently a growing area of concern. During the period between adolescence to post menopause, treatment should be considered and adjusted in line with changing (life) goals, expectations and needs.

© Bohn Stafleu van Loghum is een imprint van Springer Media B.V., onderdeel van Springer Nature 2021
E. A. P. Steegers et al. (Red.), *Textbook of Obstetrics and Gynaecology*,
https://doi.org/10.1007/978-90-368-2131-5_32

Summary

Endometriosis is a benign gynaecological disorder, characterised by endometrial-like tissue growing outside the uterine cavity under the influence of oestrogens. It affects 2 to 10 % of women of reproductive age. The exact pathogenesis has not been fully clarified, but a complex multifactorial process of immunologic, inflammatory and hormonal factors seems to be involved. Endometriosis can be suspected based on clinical symptoms and findings by physical examination and/or imaging modalities. Surgical identification, including histological verification, remains the gold standard for the diagnosis. Since curative treatment options for endometriosis are not available, treatment is challenging. Symptomatic treatment of this chronic disease consists of analgesia, hormonal suppression therapy and/or surgical intervention. In infertile women assisted reproductive techniques may be considered. A multidisciplinary and life course approach is advocated.

32.1 Introduction – 3

32.2 Etiology of endometriosis – 3

32.3 Pathophysiology/symptoms of endometriosis – 3
32.3.1 Pain – 3
32.3.2 Infertility – 4

32.4 Classification of endometriosis – 4

32.5 Diagnosis of endometriosis – 4
32.5.1 History – 4
32.5.2 Physical examination – 4
32.5.3 Imaging – 5
32.5.4 Biomarkers – 6
32.5.5 Laparoscopy – 6
32.5.6 Other diagnostic modalities – 7

32.6 Treatment of endometriosis – 8
32.6.1 Surgical treatment of endometriosis related pain – 10
32.6.2 Treatment for endometriosis related infertility – 11

32.7 Endometriosis in pregnancy – 12

32.8 Endometriosis and menopause – 14

32.9 Endometriosis and cancer – 14

32.10 Social context or social determinants – 14

Glossary – 15

Key references – 16

32.1 Introduction

►Endometriosis is a common benign gynaecological disorder. It is defined as the presence of endometrial-like tissue (glands and stroma) outside the uterine cavity, growing by the influence of oestrogens, inducing a chronic inflammatory reaction. This is accompanied by angiogenesis, neural infiltration, adhesions, fibrosis and finally anatomical distortion.

The exact prevalence of endometriosis in the general population is not known and difficult to determine due to the wide variety of symptoms. Estimates range from 2 to 10 % in women of reproductive age, and up to 50 % in women presenting with infertility or chronic pelvic pain. It's estimated that more than 175 million women worldwide suffer from endometriosis; causing substantial individual impact and socioeconomic burden to many of them as a result.

The presence of intra-abdominal endometriosis can be suspected based on medical history and clinical symptoms such as dysmenorrhea, dyschezia, haematochezia, dysuria, haematuria, dyspareunia and chronic pelvic pain. Complaints are often related to the menstrual cycle and may be progressive in nature. However, symptoms can also be very mild or even absent. Although endometriosis can be suspected based on women's presenting symptoms and signs, findings by physical examination and imaging modalities (e.g., transvaginal ultrasound (TVU) and magnetic resonance imaging (MRI)), surgical identification with histological confirmation of endometriotic tissue remains the gold standard for the definitive diagnosis. Even in women without symptoms, endometriosis can be diagnosed during fertility work-up or as coincidental finding during abdominal surgery. In general, it can be stated that clinical symptoms and the experience of the patient rarely reflect the severity of the disease.

32.2 Etiology of endometriosis

The exact aetiology and pathogenesis of endometriosis is still poorly understood. Microscopic findings of endometriosis were first described by von Rokitansky in 1860, followed by Diesterweg (1883), Cullen (1896) and Russel (1899). In the 1920 s John Sampson was the first to postulate that endometriosis originated from retrograde menstruations, disseminating endometrial tissue fragments and menstrual debris from the uterine cavity through the fallopian tubes into the abdominal cavity. Still, this is the most widely accepted theory regarding the aetiology of endometriosis, although it does not fully explain the existence of endometriosis outside the peritoneal cavity. Besides, 76 to 90 % of women have some degree of retrograde menstruation, but only a fraction of them develop endometriosis. In addition, ►Sampson's theory cannot explain cases of pre- and peri-menarcheal endometriosis. This is why neonatal uterine bleedings have been proposed as a possible source of early-onset endometriosis, postulating that dissemination of endometrial stem/progenitor cells can already occur early in life, either during the neonatal endometrial shedding shortly after birth or even earlier during embryogenesis. It is therefore likely that the pathogenesis of endometriosis consists of a complex multifactorial process of genetic, environmental, immunological and hormonal factors, which is linked to the attachment of endometrial cells to the peritoneal lining, subsequent infiltration and proliferation of endometrial cells resulting in endometriotic lesions. The dissemination, implantation and proliferation of endometrial cells is also observed as an iatrogenic phenomenon after surgery, causing abdominal wall nodules in umbilical or caesarean section scars also known as incisional endometriosis.

32.3 Pathophysiology/symptoms of endometriosis

32.3.1 Pain

The presence of intra-abdominal endometrial lesions results in a variety of clinical pain symptoms such as dysmenorrhea, dyschezia, haematochezia, dysuria, haematuria, deep dyspareunia and chronic pelvic pain. The pathophysiology of endometriosis associated pain is complex and poorly understood. Pain can be the result of damaged tissue or active inflammation (nociceptive pain) and/or caused by a lesion infiltrating the somatosensory nervous system (neuropathic pain). Finally, the central nervous system is thought be involved in amplification and/or generation of endometriosis associated pain, since chronic pain is associated with changes in brain function and brain structure as well. This phenomenon is referred to as ►central sensitisation (see ►box 1). It is hypothesised that persistent nociceptive input from endometriotic tissues might result in increased responsiveness among dorsal horn neurons, processing input from the affected pelvic tissue areas. So, when central sensitisation occurs, the pain is no longer coupled to the presence, intensity, or duration of noxious peripheral stimuli.

Box 1 Clinical criteria for central sensitisation according to Levesque et al. (2018)

- Pain is disproportional to the nature and extent of pathology
- Widespread and non-anatomical distribution of pain
- History of failed medical and surgical treatments
- Chronic pain induces negative emotions and altered social life

Resting-state functional MRI can be used to study the activities of multiple brain regions and to determine brain connectivity to pain related brain regions. In recent years it became a popular modality for the study of the central sensitisation, showing an increased connectivity between anterior insula and medial prefrontal cortex (both are pain

processing regions in the brain) in women with chronic pain due to endometriosis versus pain free controls. In addition, the observed increased connectivity in endometriosis patients with chronic pain is positively correlated with neurotransmitter concentrations in anterior insula (measured by Glutamine-Glutamate concentrations by proton magnetic resonance spectroscopy) as well as with anxiety, depression and pain intensity scores.

32.3.2 Infertility

Endometriosis and ►infertility are closely related. Although the exact mechanisms are not yet fully clear, the disorder is a contributing cause of infertility in up to 50 % of couples who want to conceive. The impaired ability to conceive may be explained by an altered folliculogenesis, hostile peritoneal environment, poor oocyte quality, impaired ovarian reserve, tubal dysfunction, decreased implantation capacity of the embryo, reduced endometrial receptivity and/or concomitant adenomyosis.

32.4 Classification of endometriosis

Abdominal endometriosis can be classified between superficial (peritoneal) endometriosis, deep (pelvic) endometriosis and ovarian endometriosis. Adenomyosis is considered a separate disease entity encountered in the uterus.

Superficial or ►peritoneal endometriosis is defined as the presence of deposits of endometrial glands and stroma on the pelvic peritoneal surface and ovaries. They can induce an inflammatory reaction resulting in pelvic pain complaints and formation of adhesions in the abdominal cavity.

►Ovarian endometriosis or endometriomas are cysts formed by deposits of endometriosis within the ovary. They originate from pseudocysts that are formed by invagination of endometriotic tissue within the ovarian cortex. It is diagnosed in 17 to 44 % of women with endometriosis, and more frequently seen in women with concomitant deep endometriosis.

►Deep endometriosis is defined as endometriotic lesions extending more than 5 mm under the peritoneal surface and/or involving the bowel, bladder, ureter or vagina. Often deep endometriosis appears as nodular lesions or plaques consisting of active endometrial-like glands and cytogenous stroma, smooth muscle cells and fibrosis.

►Adenomyosis is described by the invasion of endometrial-like tissue into the myometrium, enlarging the uterine volume, with microscopically ectopic endometrial glands and stroma surrounded by hypertrophic and hyperplastic myometrium. Adenomyosis can be present in one part of the myometrium (focal adenomyosis), or involve the entire myometrium (diffuse adenomyosis) In addition, nodular lesions (adenomyoma) or cystic lesions (adenomyotic cysts) are encountered as well.

Finally, endometriosis can also be found outside the pelvic area at a distance from the genital organs. It can involve the upper abdomen, diaphragm, pleura, lungs, sciatic nerve as well as the abdominal wall.

Different scoring systems are used to stage the severity of endometriosis disease. The revised American Society for Reproductive Medicine (rASRM) staging score is the oldest system and the one most commonly used, taking into account the extension of the disease, and states endometriosis as either minimal (stage I), mild (stage II), moderate (stage III) or severe (stage IV) (◘ fig. 32.1). Deep endometriosis can be morphologically described by the Enzian score (◘ fig. 32.2) in addition to the ASRM classification. Unfortunately, the extension of endometriosis disease classified by both systems are not correlated to the severity of clinical symptoms and fertility prospects. To predict pregnancy rates in surgically diagnosed and treated women with endometriosis the Endometriosis Fertility Index (EFI) score has been developed (◘ fig. 32.3). The scoring system has been validated to predict naturally conceived pregnancies and is a promising tool to be used in selecting patients with poor prognosis, to begin with assisted reproductive techniques.

32.5 Diagnosis of endometriosis

32.5.1 History

The main goal of taking a complete history and evaluation of pain is to identify patients at risk of having endometriosis and to reduce the diagnostic delay (◘ tab. 32.1). On the other hand, one has to keep in mind that a detailed analysis of pain complaints (using visual analogue scale (VAS) or numerical rating scale (NRS)) lacks accuracy in predicting the location and severity of endometriosis. Using VAS or NRS for pain measurement, combined with a quality-of-life scale, provides an instrument for evaluating treatment effects. The Endometriosis Health Profile (EHP-30) is a validated questionnaire which provides a non-biased tool in the assessment of quality of life.

32.5.2 Physical examination

Physical examination is essential in women suspected to have endometriosis and is aimed to facilitate a timely diagnosis. However, the absence of any abnormalities during physical examination cannot rule out the presence of endometriosis. Physical examination includes inspection and (bimanual) palpation of the abdomen, vagina, cervix, internal genital organs, uterosacral ligaments and rectovaginal septum. Findings during physical examination that can enhance the suspicion of endometriosis are; visible red, blue or haemorrhagic vaginal nodules (◘ fig. 32.4), tender masses or nodularities, signs of fibrosis, lateral cervix displacement, a fixed and retroverted uterus, uterine motion tenderness, a painful Pouch of Douglas and thickening or tenderness of the uterosacral ligaments or rectovaginal septum. Tender or fixed adnexal masses and adnexal enlargement can be a sign of ovarian endometriomas. Rectovaginal

AMERICAN SOCIETY FOR REPRODUCTIVE MEDICINE
REVISED CLASSIFICATION OF ENDOMETRIOSIS

Patient's Name _____ Date _____

Stage I (Minimal) - 1-5
Stage II (Mild) - 6-15
Stage III (Moderate) - 16-40
Stage IV (Severe) - > 40
Total _____

Laparoscopy _____ Laparotomy _____ Photography _____
Recommended Treatment _____
_____
Prognosis _____

PERITONEUM	ENDOMETRIOSIS	< 1cm	1-3 cm	> 3 cm
	Superficial	1	2	4
	Deep	2	4	6
OVARY	R Superficial	1	2	4
	Deep	4	16	20
	L Superficial	1	2	4
	Deep	4	16	20
	POSTERIOR CULDESAC OBLITERATION	Partial	Complete	
		4	40	
OVARY	ADHESIONS	< 1/3 Enclosure	1/3-2/3 Enclosure	> 2/3 Enclosure
	R Filmy	1	2	4
	Dense	4	8	16
	L Filmy	1	2	4
	Dense	4	8	16
TUBE	R Filmy	1	2	4
	Dense	4*	8*	16
	L Filmy	1	2	4
	Dense	4*	8*	16

*If the fimbriated end of the fallopian tube is completely enclosed, change the point assignment to 16.
Denote appearance of superficial implant types as red [(R), red, red-pink, flamelike, vesicular blobs, clear vesicles], white [(W), opacifications, peritoneal defects, yellow-brown], or black [(B) black, hemosiderin deposits, blue]. Denote percent of total described as R ____%, W ____% and B ____%. Total should equal 100%.

Figure 32.1 Revised American Society for Reproductive Medicine Classification of Endometriosis. Reprinted with permission from Elsevier from *Fertil Steril* 1997;67:817–821

digital examination can be considered, looking for tender masses, nodules or fibrosis, when involvement of the rectosigmoidcolon is suspected. The quality of the examination is determined by the experience and skills of the clinician.

32.5.3 Imaging

The most frequently used imaging modalities for the detection of endometriosis are transvaginal ultrasound (TVU) and magnetic resonance imaging (MRI) (fig. 32.5, 32.6, 32.7, 32.8, 32.9 and 32.14).

Ultrasound

TVU is a first line non-invasive imaging tool and especially useful for the identification of bowel and bladder endometriosis, ovarian endometriomas as well as adenomyosis. TVU evaluation is accompanied with high sensitivity and specificity rates when performed by experienced clinicians. A systematic approach to examine the pelvis by TVU and describe sonographic features and the appearance of endometriosis is described in the IDEA (International Deep Endometriosis Analysis group) statement. Further examination with MRI can be considered when more extensive pelvic disease is suspected.

A promising new imaging modality is transvaginal elastosonography, which appears to be able to differentiate active endometriosis lesions from fibrotic lesions in deep endometriosis by measuring tissue stiffness.

MRI

MRI has a high diagnostic accuracy and can especially be used to assess the extent of the disease in women with adenomyosis and/or deep endometriosis. The advantage of MRI over TVU and laparoscopic inspection is the ability to make a complete survey of both the anterior and posterior compartment of the pelvis including the retroperitoneum. Especially in areas which are inaccessible to evaluation by TVU, such as the lateral pelvic wall, showing the course of the ureter. Therefore, MRI is, besides diagnosing endometriosis, also effective in assessing the extent of the disease and potential risk of organ dysfunction (e.g., hydronephrosis by distal ureter endometriosis) as well as offering a roadmap to surgery (see ▶box 2).

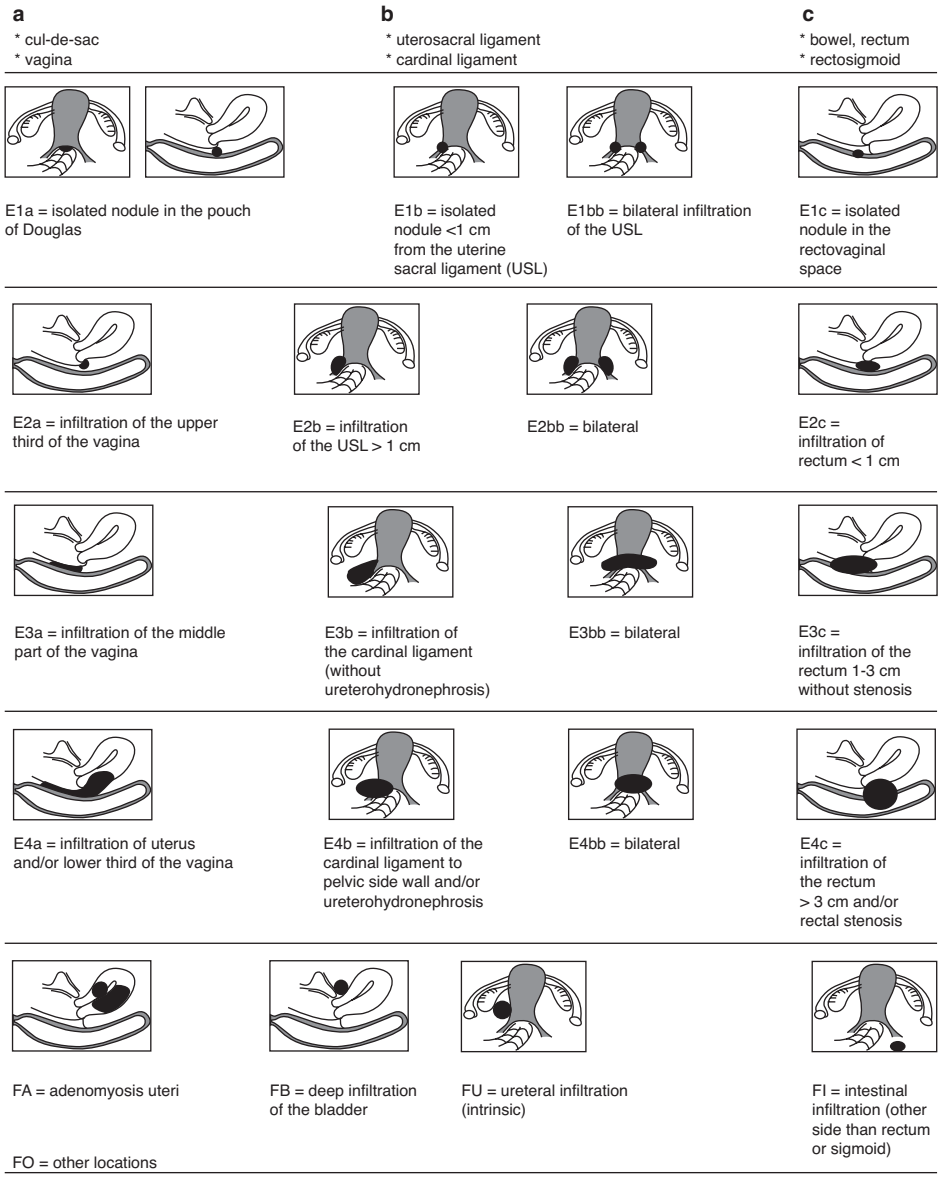

Figure 32.2 Enzian Classification of deep endometriosis. Reprinted with permission from Elsevier from *Fertil Steril* 2011;95:1574–1578

Box 2 MRI evaluation is recommended

- Suspicion of adenomyosis especially in co-existence with fibroids
- Suspicion of deep endometriosis of colorectum, ureters, bladder, vagina (fornix posterior), uterosacral ligaments, tubes (hematosalpinx), sciatic nerve and abdominal wall

32.5.4 Biomarkers

Up until now no reliable biomarkers (in serum, urine and endometrium) have been available for the non-invasive detection of endometriosis. Traditionally serum CA-125 is used for diagnosing endometriosis. However serum CA-125 has low diagnostic performance and is currently not advised to be used as well as any other biomarker in blood, endometrial tissue or urine to diagnose endometriosis.

32.5.5 Laparoscopy

Peritoneal lesions can only be visualised during laparoscopy and identification is largely dependent upon the experience of the surgeon performing the inspection (fig. 32.10, 32.11). Laparoscopic identification and histological verification of endometriotic tissue is the current gold standard for the final diagnosis of the disease although negative histology does not entirely rule out the disease. However, even for experienced surgeons it remains hard to distinguish non-pigmented endometriotic lesions from healthy peritoneal tissue. The

ENDOMETRIOSIS FERTILITY INDEX (EFI) SURGERY FORM

LEAST FUNCTION (LF) SCORE AT CONCLUSION OF SURGERY

Score		Description		Left		Right		
4	=	Normal	Fallopian Tube					
3	=	Mild Dysfunction						
2	=	Moderate Dysfunction	Fimbria					
1	=	Severe Dysfunction						
0	=	Absent or Nonfunctional	Ovary					
			Lowest Score		+		=	
				Left		Right		LF Score

To calculate the LF score, add together the lowest score for the left side and the lowest score for the right side. If an ovary is absent on one side, the LF score is obtained by doubling the lowest score on the side with the ovary.

ENDOMETRIOSIS FERTILITY INDEX (EFI)

Historical Factors			Surgical Factors		
Factor	Description	Points	Factor	Description	Points
Age			LF Score		
	If age is ≤ 35 years	2		If LF Score = 7 to 8 (high score)	3
	If age is 36 to 39 years	1		If LF Score = 4 to 6 (moderate score)	2
	If age is ≥ 40 years	0		If LF Score = 1 to 3 (low score)	0
Years Infertile			AFS Endometriosis Score		
	If years infertile is ≤ 3	2		If AFS Endometriosis Lesion Score is < 16	1
	If years infertile is > 3	0		If AFS Endometriosis Lesion Score is ≥ 16	0
Prior Pregnancy			AFS Total Score		
	If there is a history of a prior pregnancy	1		If AFS total score is < 71	1
	If there is no history of prior pregnancy	0		If AFS total score is ≥ 71	0
Total Historical Factors			Total Surgical Factors		

EFI = TOTAL HISTORICAL FACTORS + TOTAL SURGICAL FACTORS: Historical + Surgical = EFI Score

Figure 32.3 Endometriosis Fertility Index. Reprinted with permission from Elsevier from *Fertil Steril* 2010;94:1609–1615

intraoperative use of enhanced laparoscopic imaging techniques might improve the identification and treatment of endometriosis.

32.5.6 Other diagnostic modalities

There is no place to routinely perform a coloscopy or cystoscopy in the diagnostic work-up of bowel or bladder endometriosis. When mucosal pathology of the bowel of bladder is suspected these invasive diagnostics can be considered. When ureteral endometriosis is suspected a renogram, renal ultrasound and evaluation of the kidney function can be considered. In all these cases, a multidisciplinary approach is advised.

Box 3 Diagnostic steps

- Palpation of the abdomen
- Inspection of the vaginal fornix posterior
- Bimanual transvaginal palpation of the genital organs and the pelvis
- Transrectal palpation when suspecting deep endometriosis with rectal involvement
- Transvaginal ultrasound
- MRI abdomen
- Renal ultrasound and renogram when suspecting ureteral endometriosis
- Laparoscopic identification and histological verification for final diagnosis

Table 32.1 History

symptoms of endometriosis	indicative for
dysmenorrhea	endometriosis, adenomyosis, fibroids
chronic pelvic pain	endometriosis, irritable bowel syndrome, bladder pain syndrome
deep dyspareunia & sexual dysfunction	deep endometriosis of the posterior cul-de-sac, vaginal fornix posterior, adenomyosis
cyclic dyschezia & cyclic constipation	deep endometriosis of the rectosigmoid
cyclic dysuria & cyclic haematuria	deep endometriosis of the bladder & ureter
infertility	endometriosis, adenomyosis, peri-adnexal adhesions, tubal dysfunction, diminished ovarian reserve
shoulder tip pain, catamenial pneumo-thorax, cyclical cough/ haemoptysis & chest pain	thoracic endometriosis syndrome
cyclical scar swelling and pain	abdominal wall endometriosis

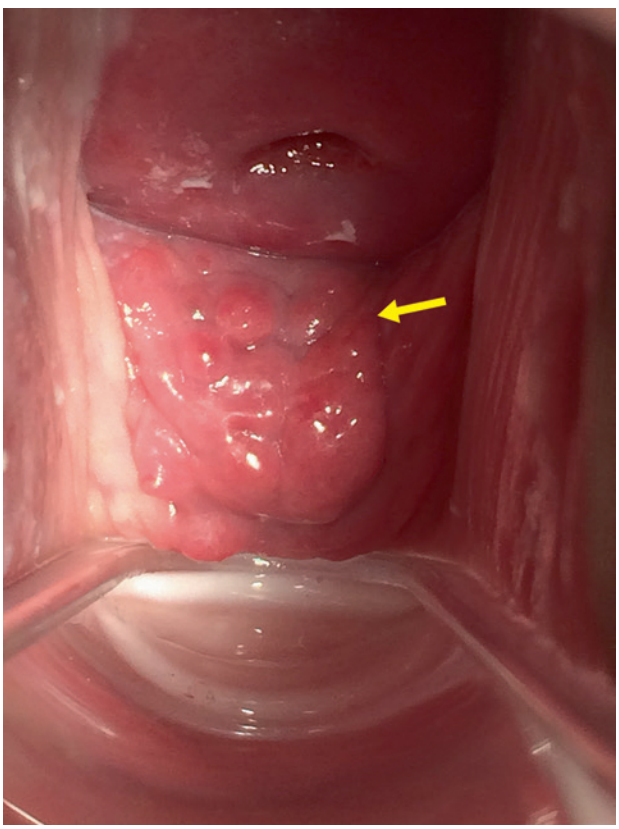

Figure 32.4 Vaginal fornix posterior with endometriosis visible as red nodules (yellow arrow)

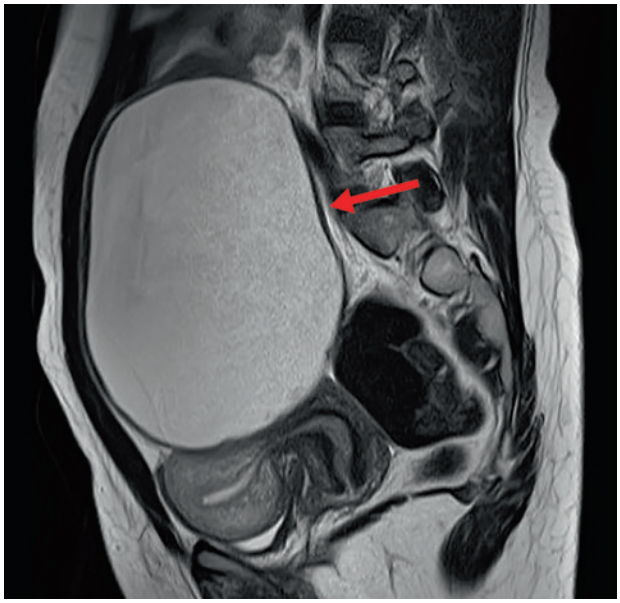

Figure 32.5 Sagittal MRI image (T2-weighted) showing an endometriosis cyst (149 × 34 × 148 mm, red arrow) in the right ovary. No signs of adenomyosis or deep endometriosis

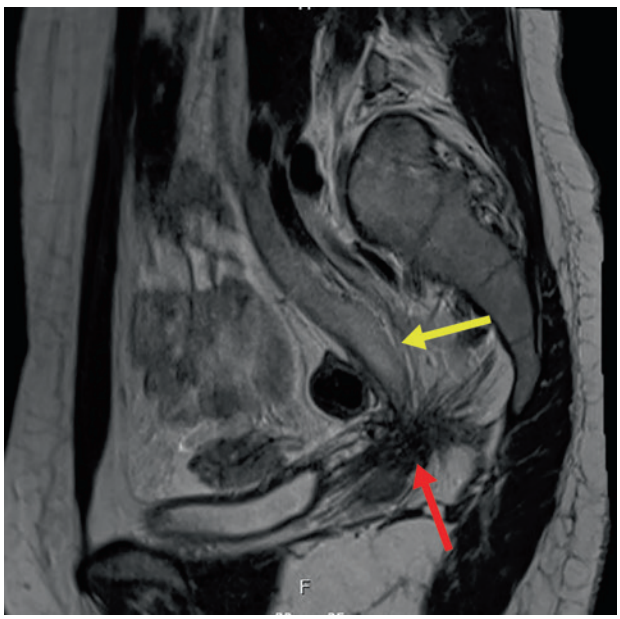

Figure 32.6 Sagittal MRI image (T2-weighted) showing endometriosis of the distal ureter left-side (red arrow) with a hydroureter (yellow arrow) prior to the occlusion

32.6 Treatment of endometriosis

Treatment of women with endometriosis is challenging, since curative treatment options are unavailable. Symptomatic treatment of this chronic disease consists of analgesia, hormonal suppression therapy and/or surgical intervention. A lifetime approach in the treatment of women with endometriosis is preferred, since this chronic disease can be progressive over time. Early diagnosis of endometriosis

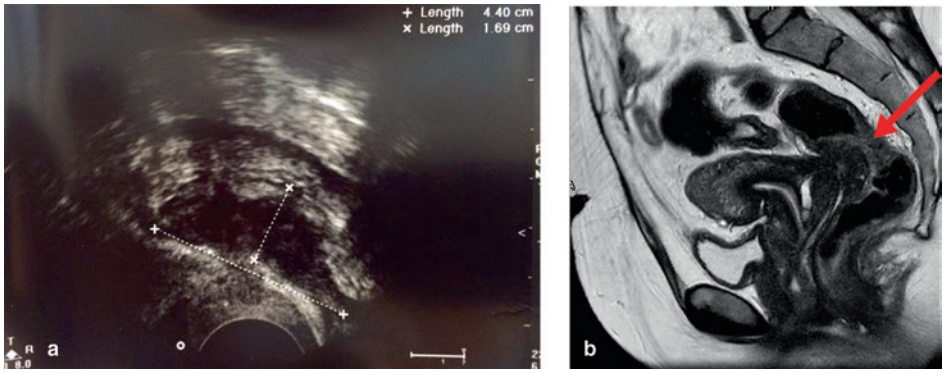

Figure 32.7 Sagittal transvaginal ultrasound image (**a**) and MRI image (T2-weighted) (**b**) showing deep endometriosis (located between the fornix posterior and torus uteri) with infiltration in anterior rectum wall (red arrow) at 7 cm from the anal verge

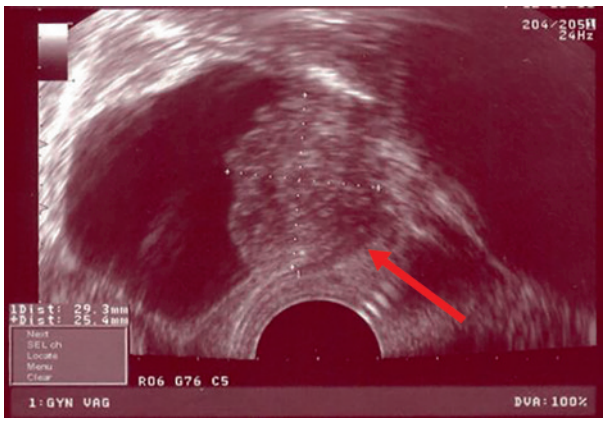

Figure 32.8 Sagittal transvaginal ultrasound image showing full thickness endometriosis (24 × 15 mm, red arrow) in the posterior bladder wall

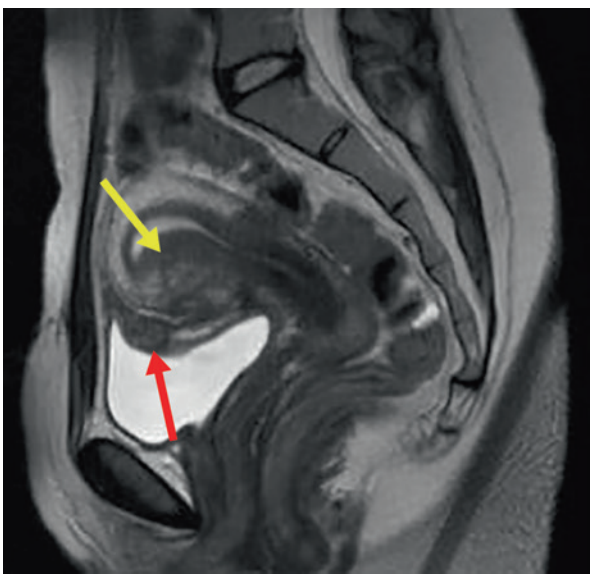

Figure 32.9 Sagittal MRI image (T2-weighted) showing focal adenomyosis (anterior uterine wall, yellow arrow) and full thickness endometriosis in the posterior bladder wall (red arrow)

may slow down progression of the disease. Over the period from adolescence until post menopause treatment should be adjusted in line (and due to) changing (life) goals, expectations and needs.

Treatment is individually tailored with reference to the ASRM and ESHRE guidelines, and should be focused on the reduction of endometriosis-related symptoms, improving quality of life and taking into account any active or latent desire to become pregnant. Women with severe (treatment resistant) complaints and/or deep endometriosis should be reviewed by a multidisciplinary team in particular. This team should consist of at least a gynaecologist, radiologist, colorectal surgeon and urologist. Preferably an anaesthesiologist/pain expert, psychologist, gastroenterologist and dedicated nursing staff should be included. Since pain in endometriosis is very complex, treatment should not only be focused on pharmacological and surgical options; non-pharmacological treatment options might be complementary (▶box 4). For instance, consultation and treatment of a sexologist when endometriosis is negatively affecting a sexual relationship, or a specialised physiotherapist in women with pelvic floor hypertonia as a result of (chronic) pelvic pain can be considered, as well as consultation with a psychologist to treat women with cognitive behavioural therapy, which might positively influence health related quality of life. Cognitive behaviour therapy approaches have been found particularly effective for patients showing signs of central sensitisation. It provides ways of learning to change maladaptive illness/injury perceptions. It may alter maladaptive pain thoughts and behaviour patterns as well.

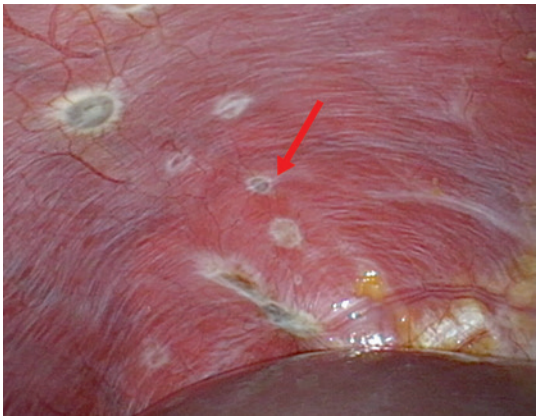

Figure 32.10 Laparoscopic view showing endometriosis spots (red arrow) on the abdominal side of the right diaphragm. Bottom of the picture shows the upper side of the liver

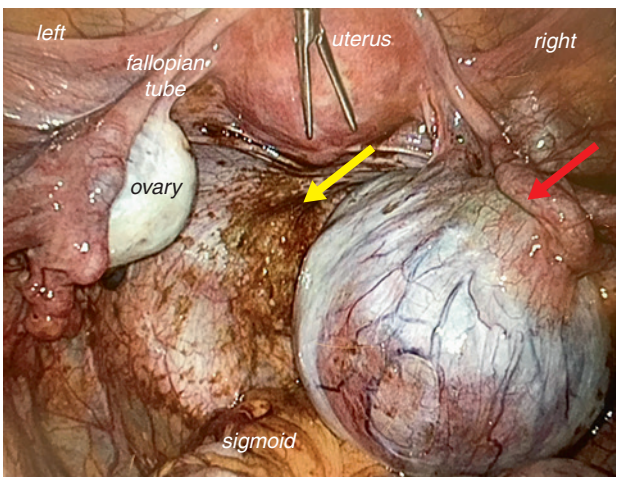

Figure 32.11 Laparoscopic view showing an enlarged ovary on the right side due to an endometriotic cyst (red arrow) accompanied by peritoneal depositions of endometriosis in the Douglas cavity (yellow arrow)

Box 4 Pain management (non-hormonal & non-surgical) of endometriosis

- **Pain relievers**
- COX-I & II inhibitors: naproxen, ibuprofen, celecoxib
- Anti-epileptics (used in central sensitization): pregabaline, gabapentine,
- Anti-depressants (used in central sensitization): amitriptylin, nortriptylin, duloxetine
- Opioids: tramadol, tapentadol, buprenorphine, fentanyl, morphine, oxycodon, hydromorphone, methadone
- Spasmolytics: buscopan, metamizol (off-label)
- **Non interventional treatment**
- TENS (Transcutaneous Electrical Nerve Stimulation)
- Cognitive behaviour therapy
- **Interventional treatment**
- Superior and inferior hypogastric plexus block
- Lumbal epidural steroid injection
- Caudal epidural block
- Pudendal nerve block

Since endometriosis is an oestrogen-dependent disease, hormonal suppression of the menstrual cycle is the cornerstone in the medical treatment of endometriosis. By shared decision making, different hormonal treatment options can be considered and chosen, taking into account patients preferences, side-effects, efficacy, costs and local availability. Hormonal contraceptives (preferably in a continuous regime), progestogens, anti-progestogens or GnRH agonist/antagonists are all proven to reduce endometriosis-related pain complaints.

32.6.1 Surgical treatment of endometriosis related pain

Surgical treatment of endometriosis is particularly indicated if a patient is not responding to hormonal suppression therapy, a histological confirmation of endometriosis is wanted, or if deep endometriosis leads to pelvic organ dysfunction and decreased quality of life.

The presence of peritoneal endometriosis is associated with abdominal pain and can be surgically treated by excision or ablation. It is shown that the excision or ablation of all peritoneal endometriosis lesions, in combination with adhaesiolysis to restore pelvic anatomy, effectively reduces pain. However, recurrence of endometriosis occurs in up to half of the surgically treated patients.

A direct relationship between the presence of endometrial cysts and pain has not been demonstrated. It is thought that pain is the result of the co-existence of peritoneal or deep endometriosis. Although there is no evidence that a cystectomy has a positive effect on pain complaints, cystectomies are commonly performed worldwide in both symptomatic and asymptomatic women with the intention to reduce pain and resolve infertility. However, several studies showed that healthy ovarian tissue is accidentally removed during cystectomy, which may contribute to a lower ovarian reserve and decrease in the chances for accomplishing a successful pregnancy in the future. Alternative treatments to a stripping cystectomy include (partial) ablation of the endometriosis cyst wall using the CO_2 laser and Argon plasma energy.

The effect of surgery of deep endometriosis on pain has especially been investigated in women with rectovaginal and colorectal involvement, but prospective studies are limited. A variety of surgical procedures are described, such as segmental resection (fig. 32.12), discoid resection, shaving of the bowel or superficial excision of nodules. Complications after radical surgery seem to be more severe compared to conservative surgical procedures. However, recurrence of disease might be less common after radical surgery. Since expertise in surgical treatment of deep endometriosis is preferred, it is recommended to refer women with deep endometriosis requiring surgery to a centre of expertise offering all available treatment options in a multidisciplinary setting. Surgery is also advised in case of abdominal wall endometriosis, at which nodules are formed in umbilical or

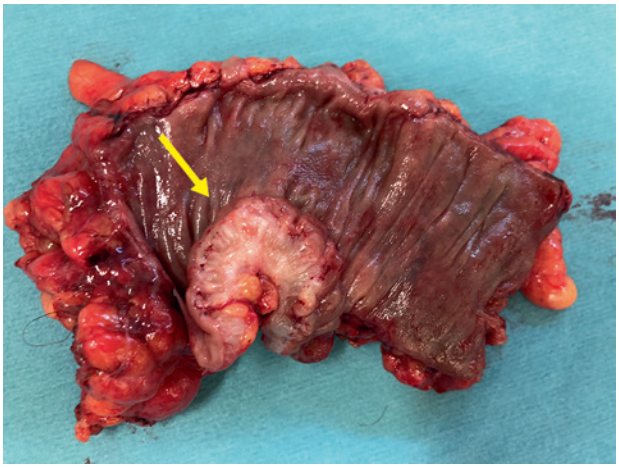

Figure 32.12 Pathologic specimen after low anterior resection showing submucosal endometriosis in the anterior rectum wall (yellow arrow)

caesarean scars (fig 32.13, 32.14 and 32.15). Also endometrial nodules at the location of an episiotomy are described. Those iatrogenic endometriosis lesions are able to invade local tissues, possibly due to the appearance of somatic cancer driver mutations as in deep endometriosis. Radical excision is advised if hormonal suppression therapy is insufficient in reducing complaints, whereby repair of underlying structures might be needed due to invasiveness of endometriosis nodules.

32.6.2 Treatment for endometriosis related infertility

How to treat women with endometriosis willing to conceive is challenging, taking into account the heterogeneity, chronic and progressive character of this disease, and the limited quantity of high-quality evidence. This applies to all manifestations of endometriosis, including deep endometriosis and adenomyosis. Since the severity of endometriosis classified by the ASRM as minimal, mild, moderate or severe endometriosis is not related to pregnancy rates, treatment should be individually tailored, taking into account the severity of endometriosis related pain complaints, the effectiveness of hormonal suppression therapy on the number of complaints and previously performed surgical interventions. In women with absence of endometriosis related pain, choice of treatment is dependent on the patency of the fallopian tubes, duration of subfertility, the co-existence of semen pathology and ability to have (regular) intercourse (i.e., lack of dyspareunia). Care must be taken to prevent over-treatment by advising immediate ►assisted reproductive techniques (ART) in this group of women with endometriosis. Women with endometriosis requiring hormonal suppression therapy due to endometriosis related pain or expectation of progression of endometriosis related complaints, assisted reproductive techniques like ►intrauterine insemination (IUI) or ►in vitro fertilization/intracytoplasmic sperm injection (IVF/ICSI) should be considered immediately after cessation of hormonal therapy. To reduce the risk on recurrence of endometriosis related pain, the duration of cessation of hormonal suppression therapy should be limited in time. In patients with recurrence or progression of endometriosis related pain, or those refusing hormonal suppression therapy, surgery should be considered to reduce the number of complaints and to restore pelvic organ dysfunction.

To routinely perform surgery in endometriosis patients and in particular where the objective is to improve pregnancy rates is debated. Ablation or excision of peritoneal endometriosis and adhaesiolysis can be performed to improve naturally conceived pregnancy rates (number needed to treat = 8). To what extent treatment of peritoneal endometriosis relates to the odds of becoming pregnant after ART is insufficiently investigated, but possibly has a beneficial effect. Based on observational data a cystectomy of endometriosis cysts to improve naturally conceived pregnancy rates may be considered. Since a cystectomy does not improve IVF/ICSI pregnancy rates, and no randomised trials are available concerning surgical treatment of deep endometriosis in improving pregnancy rates, it is advised to be reluctant to routinely perform surgery in women without endometriosis related symptoms just to improve pregnancy rates. However, if IVF/ICSI is technically impossible to be performed safely, surgery can be considered to improve the accessibility of the ovaries and to reduce the risk of IVF/ICSI related complications.

In addition to the impact on pregnancy rates, the potential complications of surgery, and the time remaining to term of the pregnancy should be taken into account in treatment decision making. Often, former surgery has been performed, and it is generally accepted to limit repeating surgery in order to reduce the risk of adhesion formation and iatrogenic damage to the ovaries. Possibly, new surgical techniques and instruments might be less detrimental to the ovary, for instance by using laser or argon plasma energy, or using a combined approach of the stripping and ablation technique instead of a classic cystectomy.

The advantage of a surgical procedure is that postoperatively the endometriosis fertility index (EFI) score can be calculated, which can be used in treatment decision making. A low EFI score is associated with low naturally conceived pregnancy rates and might be a reason to refer immediately to IVF/ICSI treatment.

Although ART is frequently applied to overcome endometriosis-related infertility, lower success rates have been reported. Whether pregnancy outcomes after IVF/ICSI can be improved by medical or surgical pre-treatment, or applying interventions that affect endometrial receptivity, is not yet well established. The role of medical treatment of endometriosis prior to IVF/ICSI is still a matter of debate. Traditionally it was recommended to precede IVF/ICSI treatment in endometriosis patients by long term

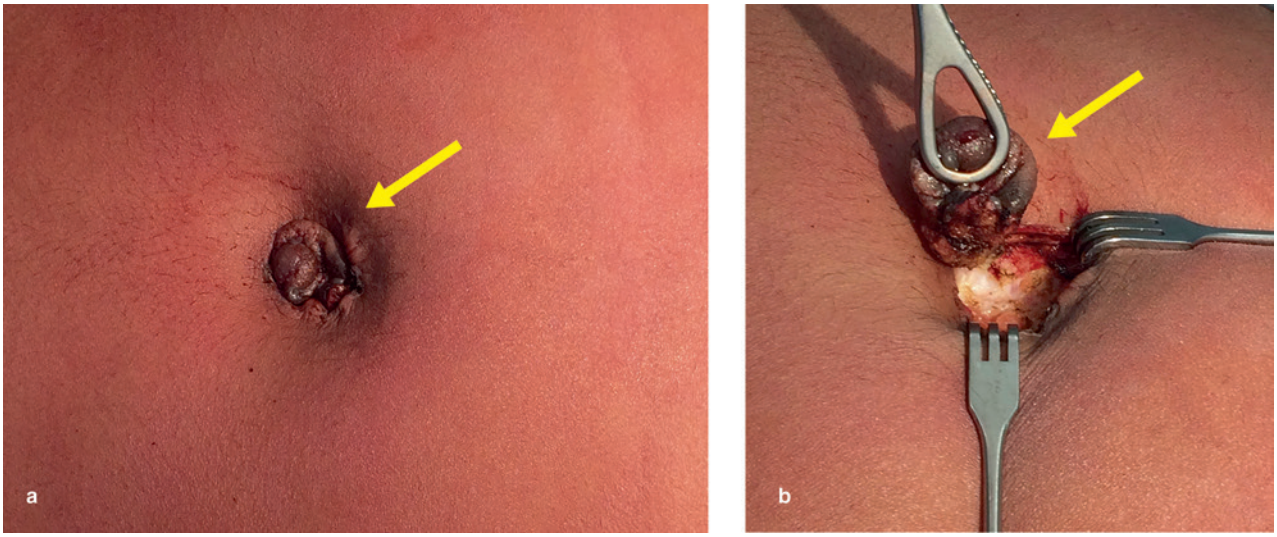

Figure 32.13 Endometriosis of the belly button prior to and after excision (yellow arrow)

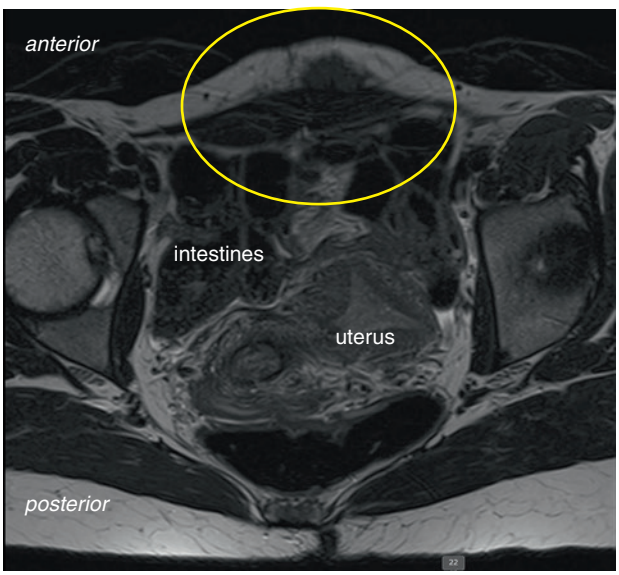

Figure 32.14 Axial MRI image (T2-weighted) of an abdominal endometriosis lesion in C-section scar (in yellow circle)

pituitary desensitisation with a GnRH agonist for three to six months to increase chances of clinical pregnancy. However high-quality trials are required to determine the effect of pre-treatment with a long-term GnRH agonist in endometriosis patients prior to IVF/ICSI and the comparison with other alternatives must be made. Besides medical treatment to enhance IVF/ICSI outcomes, it has been hypothesised that local endometrial injury might also have a beneficial effect on endometrial receptivity and implantation. However, local endometrial injury has not been shown to be effective to improve pregnancy rates in women with endometriosis related subfertility (tab. 32.2).

32.7 Endometriosis in pregnancy

Traditionally, it is believed that pregnancy has a beneficial influence on endometriosis. The concomitant amenorrhea with cessation of ovulation and the metabolic, hormonal, immune and angiogenetic changes are supposed to prevent endometriotic lesions from bleeding and expanding in pregnancy. Patients do experience less endometriosis-related complaints during and directly after pregnancy, however symptoms may rapidly recur after pregnancy. The negative influence of endometriosis on pregnancy is currently a growing area of concern. Recent literature reviews point out to a wide spectrum of negative obstetrical events possibly related to pre-existing endometriosis and adenomyosis. Most complications are rare, but some, like ▶Spontaneous Hemoperitoneum in Pregnancy (SHiP), are potentially life-threatening. Other complications described in pregnancy are intestinal perforations, complications from ovarian endometriomas (rupture, infection or enlargement), urinary tract problems, uterine rupture and endometriotic involvement in thoracic organs leading to a pneumothorax.

Endometriosis-related complications in pregnancy can be two-fold. On one hand acute complications can occur from pre-existing endometriosis, on the other hand endometriosis might have a negative impact on the physiological development of a pregnancy.

The negative role endometriosis can have on the development of pregnancies is still controversial. Pregnancy complications might be caused by a dysregulation of events that are involved in the period of implantation and placentation, leading to disturbances later in pregnancy. In the growing number of papers reporting on the relation between endometriosis and adverse obstetric outcomes, an association with ectopic pregnancies and placenta praevia seems present. There is no convincing evidence for an association

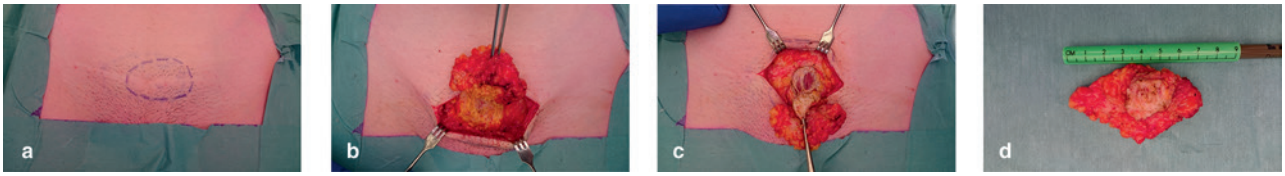

Figure 32.15 Sequence of steps taken in the surgical excision of an endometriosis lesion in the C-section scar (see fig. 32.14)

Table 32.2 Recommendations and level of evidence in treatment of endometriosis related infertility

recommendation	level of evidence
peritoneal endometriosis	
treat all visible endometriosis lesions to reduce pain	A
ablation and excision are comparable in reducing pain	C
surgery improves naturally conceived pregnancy (NNT 8)	B
surgery might improve conception rates after IUI	D
surgery might improve conception rates after IVF	C
ovarian endometriosis	
cystectomy is superior to ablation concerning recurrence of cysts, recurrence of pain and naturally conceived pregnancy	A
cystectomy might be considered to improve naturally conceived pregnancy rates	D
a cystectomy prior to ART doesn't improve pregnancy rates	A
a cystectomy might result in a decreased ovarian reserve; This has no detrimental effect on IVF/ICSI pregnancy rates	B C
a combination of stripping and ablation might result in less iatrogenic damage to the ovarian tissue compared to a cystectomy	D
surgery can be considered to improve pain and accessibility of follicles and to reduce IVF related complications	GPP
deep endometriosis	
surgery results in a decrease of complaints and an increased patient satisfaction	B
surgery combined with IVF improves pregnancy rates compared to IVF alone	D
adenomyosis is negatively associated with pregnancy rates in patients undergoing IVF	B
effect on pregnancy rates is not well established	C
surgery of deep endometriosis is advised to be performed in a centre of expertise	GPP
ART	
IUI might improve pregnancy rates and is advised to be combined with COH and should begin within 6 months after surgery	C
evidence is insufficient to conclude that long term pituitary desensitisation with a GnRH agonist prior to IVF/ICSI improves pregnancy rates or diminishes complication rates	B
endometriosis recurrence rates are not increased after IVF/ICSI	C

NNT number needed to treat; *IUI* intrauterine insemination; *IVF* in vitro fertilization; *ICSI* intracytoplasmic sperm injection; *ART* assisted reproductive techniques; *GnRH* gonadotropin releasing hormone. Quality of evidence and corresponding level of evidence (adjusted from GRADE[26] and as used in the ESHRE guideline[16]). Level A evidence (high quality): meta-analysis of multiple RCTs of high quality. Level B evidence (moderate quality): meta-analysis of multiple RCTs of moderate quality; single RCT; large non-randomized trials; case control/cohort studies of high quality. Level C evidence (low quality): single RCT; large non-randomized trials; case control/cohort studies of moderate quality. Level D evidence (very low quality): non-analytic studies, case reports/case series of high/moderate quality. Good practice point (GPP): Recommendation based on expert opinion.

between endometriosis and miscarriages, preterm births, hypertensive disorders, obstetric haemorrhages, small for gestational age babies and gestational diabetes mellitus. Additionally, there is no evidence that hormonal or surgical treatment of endometriosis prior to pregnancy lowers the risk of obstetrical complications.

32.8 Endometriosis and menopause

Although endometriosis is typically a premenopausal disease, there are some cases of postmenopausal manifestations of endometriosis. The hypo-estrogenic postmenopausal state may relieve endometriosis related symptoms, but may also trigger climacteric symptoms. The safety of hormone replacement therapy (HRT) in women with a history of endometriosis is however poorly investigated. Exogenous administration of oestrogens may influence endometriotic deposits and worsen complaints of endometriosis by reactivation, or may even result in malignant transformation of residual endometriotic tissue. However due to the lack of high-quality research, the true impact of postmenopausal use of HRT is yet unknown. Besides which cases of aggravation of endometriosis related symptoms after menopause without the use of HRT or increased endogenous oestrogen production have also been described. Pain and abnormal vaginal bleeding are most common presenting symptoms of recurrence of endometriosis in menopause. Surgical excision of endometriotic tissue, sometimes with additional medical therapy, is the required treatment for postmenopausal recurrence of endometriosis.

32.9 Endometriosis and cancer

Endometriosis is considered to be a benign condition, but has cancer-like features such as invasive growth patterns, chronic inflammatory milieu and resistance to apoptosis. Currently, based on a systematic review and meta-analysis of 49 cohort or case-control studies, endometriosis is associated with a small and non-significant increased risk of cancer overall. Endometriosis is associated with an increased risk of ovarian cancer, specifically the clear-cell and endometrioid subtypes. Despite the efforts to uncover the genetics of endometriosis, identifying individual endometriosis patients at high-risk for ovarian cancer is still not possible. There is also concern whether hormonal treatment for endometriosis may increase cancer risk as oral contraceptives are associated with an increased risk of breast and cervical cancer, whereas the risks of ovarian, endometrial and colorectal cancer are lowered. On the other hand, there is uncertainty whether surgical excision of endometriosis, from the ovaries as well as from other pelvic locations, may reduce the risk of subsequent ovarian cancer. Patients with endometriosis may request follow up (including physical examination and/or pelvic imaging), although evidence of benefit is currently lacking. Therefore, regular cancer screening is not recommended in patients with endometriosis.

32.10 Social context or social determinants

Traditionally, it was believed that endometriosis predominantly occurred in adulthood. However, endometriosis does occur in adolescents and young adults too. Moreover, a lot of adult endometriosis patients experience their first symptoms during adolescence. A review shows that in 62 % of the adolescents in whom a laparoscopy has been performed for the evaluation of dysmenorrhea or chronic abdominal, endometriosis was established. This percentage rises to 75 % if the laparoscopy is performed in situations of chronic abdominal pain insufficiently responsive to medical therapy. In 62 % of the adolescents combined cyclical and acyclical abdominal pain symptoms are reported. More often than in adults, dysmenorrhea is accompanied by nausea. In addition, migraines are more commonly reported by adolescents with endometriosis than in controls. Finally, the impact on quality of life is considerable: adolescents with endometriosis show a significantly decreased quality of life, both on the physical and mental level, in comparison to peers without endometriosis. Pain seems to be an important explanatory factor as it is leads to reduced participation in social and daily life activities.

Although the impact of endometriosis is high in adolescents the awareness of menstrual problems and endometriosis is low. Educational programmes on menstrual health, given routinely at schools, have been shown to raise the awareness of endometriosis and improve health-seeking behaviour among their audiences. Endometriosis has a profound effect on quality of life, especially when women suffer from dyspareunia and chronic pelvic pain. Although medical and surgical treatment offers a somatic basis to treat the disease, endometriosis care should also address emotional, sexual and social problems.

Perspectives

- Women with endometriosis require individualised care over a long-term period. A multidisciplinary approach to both diagnosing and treating endometriosis is needed in order to optimise care for women with (suspected) endometriosis. Centralisation of endometriosis care in expertise centres can contribute to that.
- More research is needed to establish whether an improved detection of endometriosis affects long-term clinical outcomes. Additionally research is needed to investigate the use of enhanced laparoscopic imaging techniques in surgery for deep endometriosis and its additional value regarding efficacy and safety.
- More insight in the mechanisms that are responsible for the lower pregnancy rates in endometriosis patients is needed in order to develop innovative treatment strategies. Since ART treatment is often applied to overcome endometriosis-related subfertility, it is of importance to investigate whether medical of surgical pretreatment of endometriosis can improve reproductive outcomes.

- The effect of surgical pretreatment of deep (colorectal) endometriosis on reproductive outcomes remains a matter of debate. Only observational studies are available, coming to different conclusions, with high heterogeneity and risk of bias. Therefore, the routine performance of a risky procedure to enhance fertility in women without occlusive symptoms of colorectal endometriosis should be questioned and there is a need for high quality evidence from randomised trials.
- Endometrial receptivity seems to be pivotal in establishing a successful pregnancy and may limit ART success in women with endometriosis. Identifying defects in endometrial receptivity may provide possible future treatment strategies. As such, more information is needed about the mechanisms of progesterone resistance in the endometrium of endometriosis patients: how is it developed and is it possible to reverse the resistance by medical or surgical therapy?
- Women with bilateral endometriosis cysts and the need for repeated ovarian surgery are particularly at risk of reduced ovarian reserve. They may benefit from techniques such as oocyte and ovarian cortex freezing (which have improved over time). Before routinely fertility preservation is taken into consideration, studies are needed to provide data on efficacy, safety and costs.
- Large population-based cohort studies are needed to clarify the relationship between endometriosis and adverse pregnancy outcomes. In order to develop screening or preventive interventions for pregnant women with endometriosis, future research should focus on the potential biological pathways underlying the relationship between endometriosis and adverse pregnancy outcomes.

Highlights

- Endometriosis is a common benign gynaecological disorder, defined as the presence of endometrial-like tissue outside the uterine cavity.
- The exact aetiology and pathogenesis of endometriosis is even today still poorly understood.
- Endometriosis can be suspected based on women's medical history and clinical symptoms such as dysmenorrhea, dyschezia, haematochezia, dysuria, haematuria, dyspareunia and chronic pelvic pain. Complaints are often related to the menstrual cycle and may be progressive in nature. Physical examination and imaging modalities can enhance the suspicion of endometriosis, however surgical identification with histological verification of endometriotic tissue remains the gold standard for the definitive diagnosis.
- Women with endometriosis require individualised and multidisciplinary care, with hormonal and surgical treatment being the cornerstones of endometriosis-therapy.
- Although endometriosis is typically a disease of women of reproductive age, it also affects young adults, adolescences, and women in peri- and post menopause.
- Endometriosis is considered to be a benign condition, but has cancer-like features and is associated with an increases risk of ovarian cancer.

Glossary

Adenomyosis the invasion of endometrial-like tissue into the myometrium, enlarging the uterine volume, with microscopically ectopic endometrial glands and stroma surrounded by hypertrophic and hyperplastic myometrium.

Assisted reproductive techniques (ART) all fertility treatments in which either sperm, eggs or embryos are handled.

Central sensitisation chronic pain associated changes in brain function and brain structure, resulting in an amplification and/or generation of endometriosis related pain.

Deep endometriosis endometriotic lesions extending more than 5 mm under the peritoneal surface and/or involving bowel, bladder, ureter or vagina.

Endometriosis a common benign gynaecological disorder. It is defined as the presence of endometrial-like tissue (glands and stroma) outside the uterine cavity, growing by the influence of oestrogens, inducing a chronic inflammatory reaction.

Infertility the inability to conceive after at least 1 year of unprotected intercourse.

Intrauterine insemination (IUI) artificial insemination of washed and concentrated sperm, which is directly placed in the uterus during ovulation.

In vitro fertilisation/intracytoplasmic sperm injection (IVF/ICSI) fertilisation of an egg with sperm in a laboratory setting.

Ovarian endometriosis (or endometriomas) cysts formed by deposits of endometriosis within the ovary.

Peritoneal endometriosis the presence of deposits of endometrial glands and stroma on the pelvic peritoneal surface and ovaries.

Sampson's theory theory on the pathogenesis of endometriosis based on observations of shed endometrial cells into the abdominal cavity through the fallopian tubes.

Spontaneous Hemoperitoneum in Pregnancy (SHIP) spontaneous (non-traumatic) intraperitoneal bleeding during pregnancy (up to 42 days postpartum).

Key references

1. Zondervan KT, Becker CM, Missmer SA. Endometriosis. N Engl J Med. 2020 Mar 26;382(13):1244–56.
2. Dunselman GA, Vermeulen N, Becker C, Calhaz-Jorge C, D'Hooghe T, De Bie B, Heikinheimo O, Horne AW, Kiesel L, Nap A, Prentice A, Saridogan E, Soriano D, Nelen W; European society of human reproduction and embryology. ESHRE guideline: management of women with endometriosis. Hum Reprod. 2014 Mar;29(3):400–12.
3. Guerriero S, Condous G, Van den Bosch T, Valentin L, Leone FPG, Van Schoubroeck D, Exacoustos C, Installé AJF, Martins WP, Abrao MS, Hudelist G, Bazot M, Alcazar JL, Gonçalves MO, Pascual MA, Ajossa S, Savelli L, Dunham R, Reid S, Menakaya U, Bourne T, Ferrero S, Leon M, Bignardi T, Holland T, Jurkovic D, Benacerraf B, Osuga Y, Somigliana E, Timmerman D. Systematic approach to sonographic evaluation of the pelvis in women with suspected endometriosis, including terms, definitions and measurements: a consensus opinion from the International Deep Endometriosis Analysis (IDEA) group. Ultrasound Obstet Gynecol. 2016;48:318–32.
4. De Ziegler D, Borghese B, Chapron C. Endometriosis and infertility: pathophysiology and management. Lancet. 2010;376:730–8.
5. Duffy JM, Arambage K, Correa FJ, Olive D, Farquhar C, Garry R, Barlow DH, Jacobson TZ. Laparoscopic surgery for endometriosis. Cochrane Database Syst Rev. 2014 Apr 3;(4):CD011031.
6. Gupta D, Hull ML, Fraser I, Miller L, Bossuyt PM, Johnson N, Nisenblat V. Endometrial biomarkers for the non-invasive diagnosis of endometriosis. Cochrane Database Syst Rev. 2016 Apr 20;4(4):CD012165.
7. Georgiou EX, Melo P, Baker PE, Sallam HN, Arici A, Garcia-Velasco JA, Abou-Setta AM, Becker C, Granne IE. Long-term GnRH agonist therapy before in vitro fertilisation (IVF) for improving fertility outcomes in women with endometriosis. Cochrane Database Syst Rev. 2019;11:CD013240.
8. Vercellini P, Viganò P, Frattaruolo MP, Borghi A, Somigliana E. Bowel surgery as a fertility-enhancing procedure in patients with colorectal endometriosis: methodological, pathogenic and ethical issues. Hum Reprod. 2018 Jul 1;33(7):1205–11.
9. Johnson NP, Hummelshoj L, Adamson GD, Keckstein J, Taylor HS, Abrao MS, Bush D, Kiesel L, Tamimi R, Sharpe-Timms KL, Rombauts L, Giudice LC; World Endometriosis Society Sao Paulo Consortium. World endometriosis society consensus on the classification of endometriosis. Hum Reprod. 2017 Feb;32(2):315–24.
10. Leone Roberti Maggiore U, Ferrero S, Mangili G, Bergamini A, Inversetti A, Giorgione V, Viganò P, Candiani M. A systematic review on endometriosis during pregnancy: diagnosis, misdiagnosis, complications and outcomes. Hum Reprod Update. 2016 Jan-Feb;22(1):70–103.
11. Levesque, et al. Clinical criteria of central sensitization in chronic pelvic and perineal pain (convergences PP criteria): elaboration of a clinical evaluation tool based on formal expert consensus. Pain Med. 2018 Oct 1;19(10):2009–15.
12. Lier MCI, Malik RF, Ket JCF, Lambalk CB, Brosens IA, Mijatovic V. Spontaneous hemoperitoneum in pregnancy (SHiP) and endometriosis – a systematic review of the recent literature. Eur J Obstet Gynecol Reprod Biol. 2017 Dec;219:57–65.
13. Vd Houwen LEE. Proefschrift: endometriosis associated subfertility – surgical treatment and assisted reproduction techniques. 2019
14. Lier MCI. Proefschrift: endometriosis – from diagnosis to implantation and pregnancy. 2021.